



## RESEARCH ARTICLE

# Rare pigmented variant of dermatofibrosarcoma protuberans in one case

Imane BOUJGUENNA<sup>1</sup> | Fatima BOUKIS<sup>1</sup> | Yassine BENCHAMKHA<sup>2</sup> | Kenza KANDRI RODY<sup>3</sup> | Ouafa HOCAR<sup>3</sup> | Said AMAL<sup>3</sup> | Anass FAKHRI<sup>1</sup> | Hanane RAIS<sup>1</sup>

<sup>1</sup>pathological anatomy department;  
MOHAMMED VI university  
hospital center in  
Marrakech-MOROCCO

<sup>2</sup>plastic surgery department;  
MOHAMMED VI university  
hospital center in  
Marrakech-MOROCCO

<sup>3</sup>dermatology department;  
MOHAMMED VI university  
hospital center in  
Marrakech-MOROCCO

### Abstract

The bednar tumor is a rare variant of dermatofibrosarcoma protuberans. Also known as pigmented dermatofibrosarcoma protuberans, this tumor is intermediate grade. It is observed in adults and has a predisposition to affect the shoulder area. We report a rare case of Bednar tumor in a 19-year-old patient. The diagnosis of Bednar tumor should be made in the presence of pigmented dermo-hypodermic fusocellular proliferation. Keywords: Bednar tumor, dermatofibrosarcoma protuberans, pathological anatomy

Copyright : © 2021 The Authors. Published by Publisher. This is an open access article under the CC BY-NC-ND license (<https://creativecommons.org/licenses/by-nc-nd/4.0/>).

## 1 | INTRODUCTION

**D**ermatofibrosarcoma protuberans (DFSP) is a rare cutaneous soft tissue sarcoma of intermediate malignancy, the incidence of which peaks between the fourth and fifth decade of life. Bednar tumor, also known as pigmented DFSP, is a rare variant, accounting for less than 5% of all DFSP cases.

## 2 | MEDICAL OBSERVATION

This is a 19-year-old young woman, with no particular medical history, who presented with a congenital skin nodule gradually increasing in size for 2 years and in whom clinical examination revealed a 1.5 cm long nodule. localized on the left forearm without

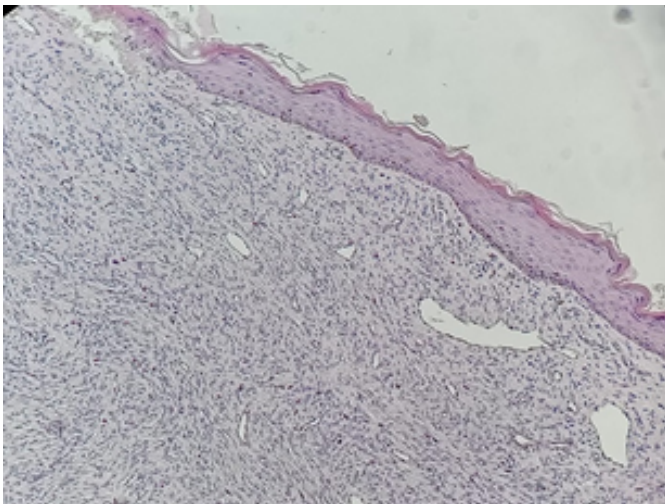
inflammatory signs opposite. The patient underwent an excisional biopsy of this lesion.

Macroscopic examination revealed a well-defined rounded mass, yellowish-white in color, of firm consistency.

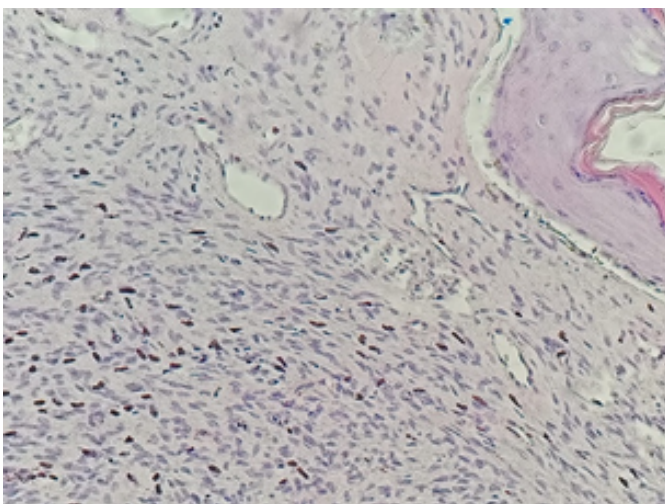
Microscopic examination of the sample received, cut in an oriented fashion and included in its entirety showed a fasciculated dermo-hypodermal mesenchymal proliferation describing a "honeycomb" appearance made up of wavy and monotonous cells co-existing with a dense sclerotic stroma. containing pseudo-vascular cracks with localized melanin pig-

**Supplementary information** The online version of this article contains supplementary material, which is available to authorized users.

mentation (1, 2) .



**FIGURE 1:** Dermo-hypodermalmesenchymal proliferation with localized melanin pigmentation (x20)



**FIGURE 2:** Dermo-hypodermalmesenchymal proliferation with localized melanin pigmentation (x40)

The immunohistochemical study performed showed diffuse and intense positivity of CD34, negativity of neurogenic and melanoma markers with a ki67 estimated at 10%.

The diagnosis retained was dermatofibrosarcoma in its pigmented variant with a deep lesion limit requiring additional surgery, the pathological examination of which after inclusion in full did not find a tumor residue.

### 3 | DISCUSSION

Bednar tumor is a rare pigmented variant of DFSP first described in 1957. It is considered an intermediate grade tumor and very rarely reported in the literature (1–3) .

It is observed in young to middle-aged adults during the fourth decade with very occasional cases in the pediatric age group (4) (5) .

The privileged sites are the region of the shoulders as well as the trunk, the extremities as in our case, the head and the neck (3–5) .

Macroscopically, Bednar's tumors appear as a poorly defined, yellowish-white mass, sometimes mucoid in appearance, localized in the dermis and hypodermis.

Histologically most Bednar tumors are located in both the dermis and the hypodermis, a few rare cases involve only the dermis, others infiltrate the underlying muscle. Most cases present with a fasciculated cell proliferation made up of wavy, monotonous cells co-existing with a dense sclerotic stroma. As in DFS a "honeycomb" appearance is frequently observed in the hypodermis as well as infiltration in large loose bundles parallel to the surface. Most cases encompass the appendices without harming them. The angiectoid and myxoid areas, when they are numerous, induce pseudo-cystic cavities of variable size, often co-existing with more sclerotic, dense areas. Many cases are hypocellular. There is no necrosis or vascular invasion, mitotic activity is rare. Exceptional myoid areas can be observed, as in DFS. Hemorrhagic foci can be observed especially in depth. Pigment-laden dendritic cells distinguish this lesion from conventional DFSP. It should be distinguished from other pigmented lesions of cutaneous spindle cells such as pigmented neurofibroma, psammomatous melanotic schwannoma, neurocystic cutaneous hamartoma and desmoplastic malignant melanoma. The overwhelming majority of cases express CD34, however intensely as DFS, and are negative for AML, desmin, HMB-45, cytokeratin and PS100 (1, 4, 6) .

On the molecular level, the alterations are completely identical to what is observed in DFS, namely a COL1A1 - PDGF $\beta$  fusion gene most often in a supernumerary ring and more rarely (pediatric forms)

a translocation 17; 22 balanced t ( 17; 22) (q22; q13) which allows a diagnosis with certainty in case of doubt (6) .

Neuroectodermal differentiation or melanocytic colonization are the two theories proposed for the histogenesis of Bednar's tumor. It has also been reported in association with cutaneous melanocytosis (Ito nevus), and based on immunohistochemistry, the originating cell is considered to be a neuromesenchymal cell. The bednar tumor may rarely undergo malignant transformation in the form of fibrosarcoma with repeated recurrence and distant metastasis. Therefore, complete excision of the lesion and close monitoring of these cases is still necessary, which is done in our case (1, 5) .

#### 4 | CONCLUSION

To conclude, although rare, it is important that histopathologists are aware and recognize this unusual entity and distinguish it from other pigmented spindle cell lesions and remember that a congenital lesion never eliminates the malignancy.

#### REFERENCES

1. Suehara Y, Yazawa Y, Hitachi K. Metastatic Bednar tumor (pigmented dermatofibrosarcoma protuberans) with fibrosarcomatous change: a case report. *Journal of Orthopaedic Science*. 2004;9(6):662–665. Available from: <https://dx.doi.org/10.1007/s00776-004-0831-2>. doi:10.1007/s00776-004-0831-2.
2. Vandeweyer E, Deraemaeker R, de Saint Aubain Somerhausen N, Geledan L, Gebhart M. Bednar Tumor of the Foot: A Case Report. *Foot & Ankle International*. 2001;22(4):339–341. Available from: <https://dx.doi.org/10.1177/107110070102200412>. doi:10.1177/107110070102200412.

3. Kaul R, Kaur N, Dogra S, Chander B. Variant of dermatofibrosarcoma protuberans: Bednar tumor. *Indian Journal of Dermatology*. 2015;60(1):107–107. Available from: <https://dx.doi.org/10.4103/0019-5154.147885>. doi:10.4103/0019-5154.147885.
4. Kaul R, Kaur N, Dogra S, Chander B. Variant of dermatofibrosarcoma protuberans: Bednar tumor. *Indian Journal of Dermatology*. 2015;60(1):107–107. Available from: <https://dx.doi.org/10.4103/0019-5154.147885>. doi:10.4103/0019-5154.147885.
5. Goncharuk V, Mulvaney M, Carlson JA. Bednar tumor associated with dermal melanocytosis: melanocytic colonization or neuroectodermal multidirectional differentiation? *Journal of Cutaneous Pathology*. 2003;30(2):147–151. Available from: <https://dx.doi.org/10.1034/j.1600-0560.2003.00030.x>. doi:10.1034/j.1600-0560.2003.00030.x.
6. Pedeutour F, Coindre JM, Sozzi G, Nicolo G, Leroux A, Toma S. supernumerary ring chromosomes containing chromosome 17 sequences: fluorescence in situ hybridization. *Cancer Genet Cytogenet*. 1993;67(2):149–149.

**How to cite this article:** I.B.O.U.J.G.U.E.N.N.A., F.B.O.U.K.I.S., Y.B.E.N.C.H.A.M.K.H.A., K.K.A.N.D.R.Y.R.O.D.Y., O.H.O.C.A.R., S.A.M.A.L., A.F.A.K.H.R.I., H.R.A.I.S. Rare pigmented variant of dermatofibrosarcoma protuberans in one case. *Clinical Medicine and Medical Research*. 2021;73–75.